

# **İMPLANT ÜSTÜ YÜKLEME PROTOKOLLERİ**

DR. MUSTAFA ZORTUK

HATAY MUSTAFA KEMAL ÜNİVERSİTESİ, DİŞ HEKİMİĞİ FAKÜLTESİ

- ☑ 1960'lı yıllarda İsveçli araştırmacı Brånemark, 'osseoentegrasyon' kavramını ve bunu takiben 'geç yükleme protokolü' konseptini tanıttı.
- ☑ Bu protokole göre yerleştirilen implantların herhangi bir protetik yükleme yapılmaksızın 3–6 ay süre ile doku altında gömülü olarak bırakılması ve osseoentegrasyon sürecinin tamamlanmasının beklenmesi gerekmektedir.

☑ Osseoentegrasyon süreci boyunca (3-6 ay) geçici hareketli protez kullanma zorunluluğu, çiğnemede zorluk çekilmesi, ağrı, protezin gevşek olması ve implantları açığa çıkarmak için ek bir cerrahi müdahaleye gerek olmasıdır.

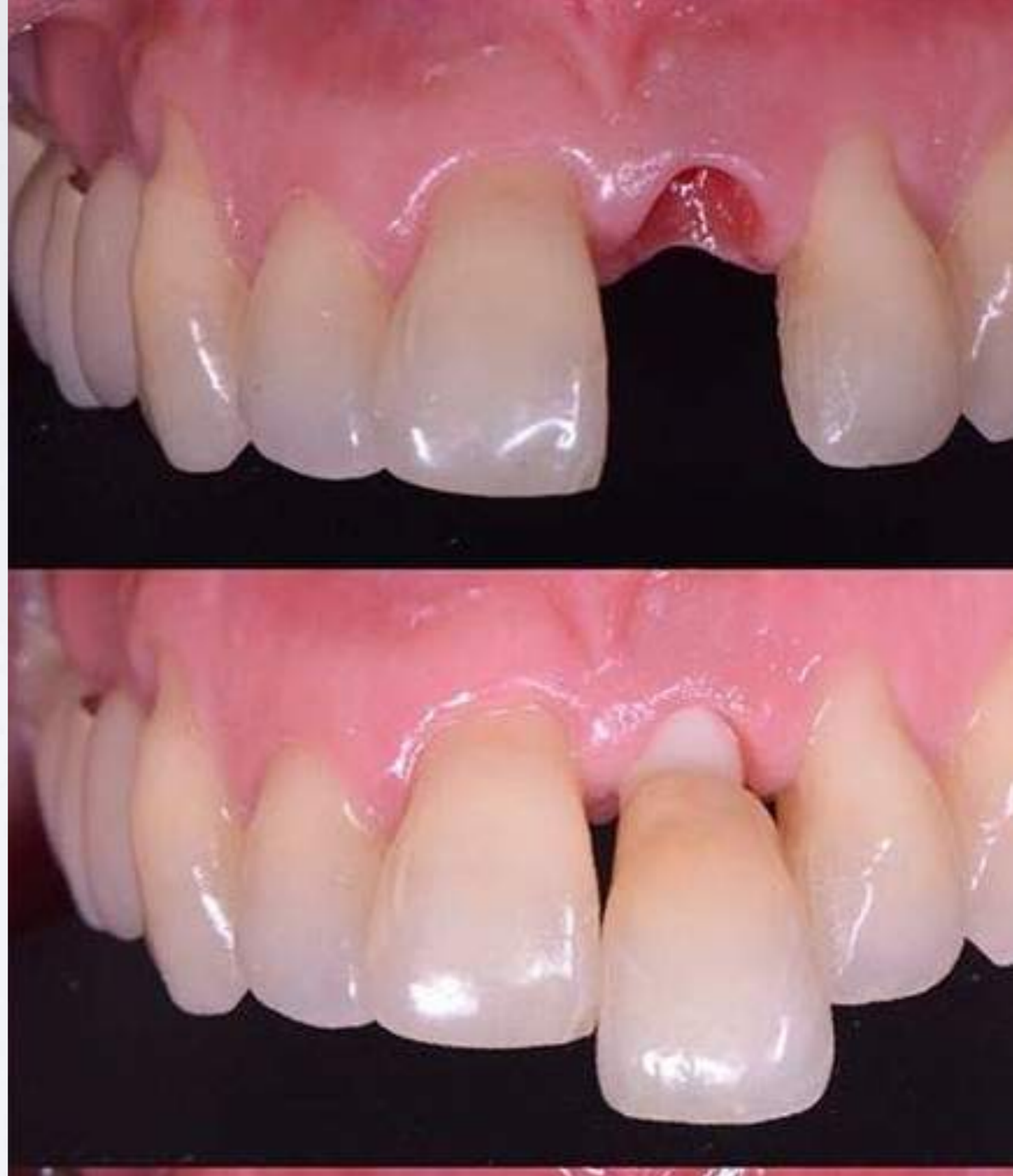

Table 3 Summary of loading protocol definitions and clarifying terms.

	<b>Immediate loading</b>	<b>Early loading</b>	<b>Conventional loading</b>	<b>Delayed loading</b>	<b>Clarifying terms</b>
<b>Barcelona Consensus 2002</b>	< 24 hours	> 24 hours < 3 – 6 months	3 – 6 months	> 3 – 6 months	Non-occlusal loading: restoration not in contact in centric occlusion
<b>ITI Consensus 2003</b>	< 48 hours	> 48 hours < 3 months	3 – 6 months	> 3 – 6 months	Immediate restoration: immediate loading without occlusal contact
<b>European Association of Osseointegration 2006</b>	< 72 hours		> 3 months (mandible) > 6 months (maxilla)	> 3 – 6 months	Immediate restoration or non-functional immediate loading defined as restoration within < 72 hours without occlusal contact
<b>Cochran Systematic Reviews 2007</b>	< 1 week	> 1 week < 2 months	> 2 months		Immediate loading with or without occlusal contact

☑️ İmplantların hemen yüklenmesi protokolü, ilk defa 1979'da Ledermann tarafından Straumann TPS implantları ile tanıtılmıştır. 'İmmediyat yükleme' ifadesi o zamandan beri kullanılabilmektedir.

☑️ Ledermann, mandibuler overdenture'ları stabilize etmek amacıyla TPS yüzeyli (Titanyum Plazma Sprey) vida şeklindeki implantları immediata olarak yüklemesidir.

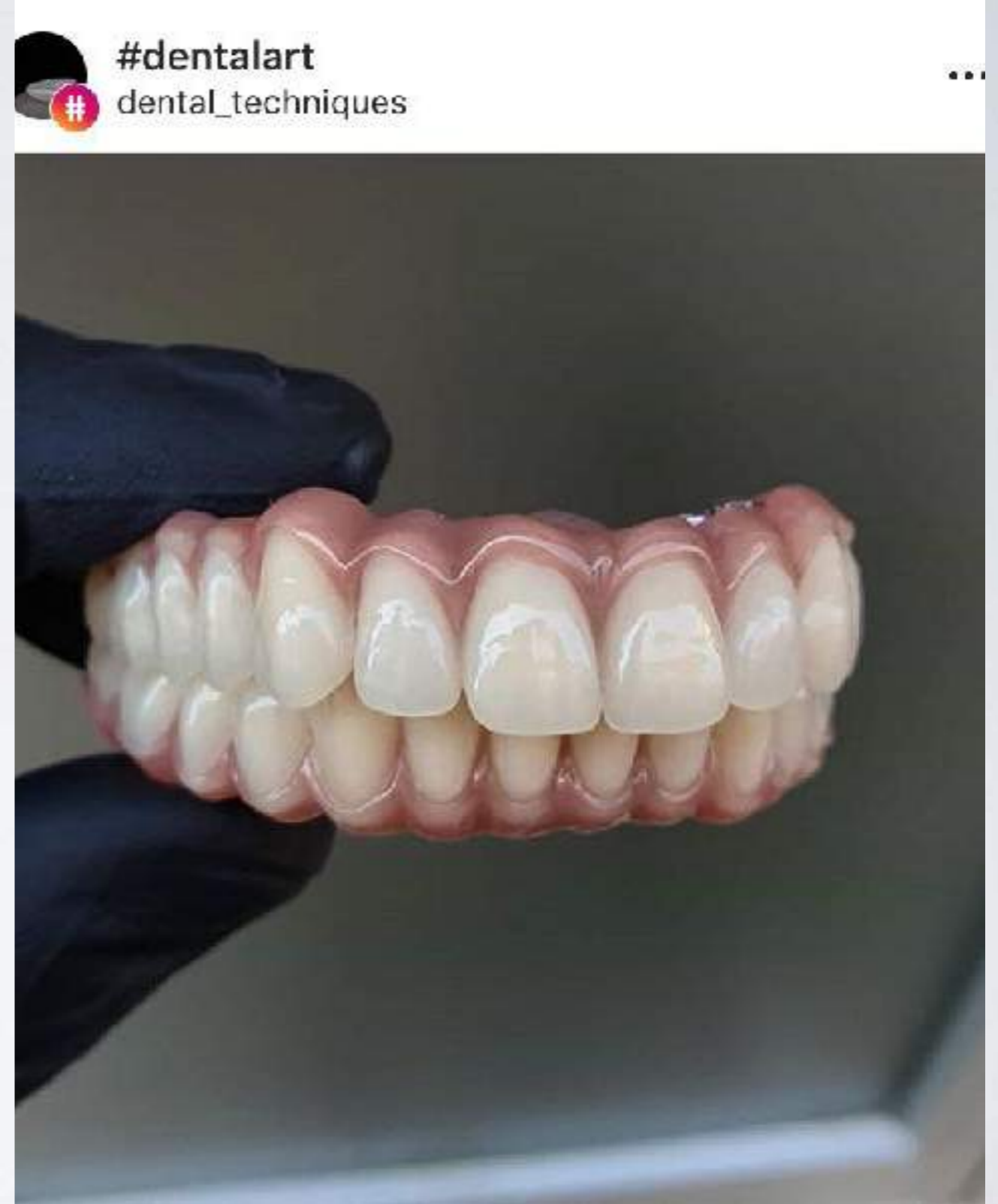


Table 1 Number of selected publications by loading protocol and prosthodontic treatment modality.

	Removable		Fixed	
	Maxilla	Mandible	Maxilla	Mandible
<b>Conventional loading</b>	3 studies 0 (RCTs) 2 (prospective) 1 (retrospective) 110 pats/530 imps 94.8% – 97.7% OH+	10 studies 4 (RCTs) 4 (prospective) 2 (retrospective) 671 pats/1396 imps 97.1% – 100% OH+	4 studies 1 (RCTs) 3 (prospective) 0 (retrospective) 104 pats/719 imps 95.5% – 97.9% OH+	4 studies 1 (RCTs) 2 (prospective) 1 (retrospective) 207 pats/1254 imps 97.2% – 98.7% OH+
<b>Early loading</b>	2 studies 0 (RCTs) 2 (prospective) 0 (retrospective) 49 pats/185 imps 87.2% – 95% OH-	4 studies 1 (RCTs) 3 (prospective) 0 (retrospective) 68 pats/136 imps 97.1% – 100% OH+	4 studies 1 (RCTs) 1 (prospective) 2 (retrospective) 54 pats/344 imps 93.4% – 99% OH+	3 studies 0 (RCTs) 2 (prospective) 1 (retrospective) 176 pats/802 imps 98.6% – 100% OH+
<b>Immediate loading</b>	1 study 0 (RCTs) 1 (prospective) 0 (retrospective) 12 pats/48 imps 95.6% OH N/A	7 studies 0 (RCTs) 6 (prospective) 1 (retrospective) 329 pats/1161 imps 96% – 100% OH+	6 studies 0 (RCTs) 5 (prospective) 1 (retrospective) 153 pats/893 imps 95.4% – 100% OH+	7 studies 0 (RCTs) 5 (prospective) 2 (retrospective) 181 pats/942 imps 98% – 100% OH+
<b>Immediate loading of immediately placed implants</b>	N/A	N/A	4 studies 0 (RCTs) 1 (prospective) 3 (retrospective) 149 pats/1194 imps 87.5% – 98.4% OH-	2 studies 0 (RCTs) 0 (prospective) 2 (retrospective) 15 pats/97 imps 97.7% – 100% OH+
<b>Total main groups</b>	<b>27</b>		<b>34</b>	
<b>Total</b>	<b>61</b>			

☑ Kısa bir zaman içinde ama farklı bir günde yükleme arasında bir ayrıma gidilmiştir.

☑ ‘İmmedyat yükleme’ terimi aynı gün protokolünü belirtirken diğer protokolün adı ‘erken yükleme’ olmuştur.

- İmplant üstü köprülerin immediat yükleme prensiplerinin ilk olarak Schnitman ve ark. (1990) tarafından açıklanmasından sonra, günümüze kadar konuyla ilgili birçok çalışma yapılmıştır. Bu amaçla dişsiz çenelerin, implantlar ile tedavileri için hemen hemen tüm markalar, immediat yüklenen tasarımlar geliştirmiştir.
- Günümüzde özellikle tek diş restorasyonlarında immediat yüklemenin başarılı bir prosedür olabileceği desteklenmekte, hatta taze çekim soketine yerleştirilen implantların immediat yüklemesinin başarısından bile söz edilmektedir.

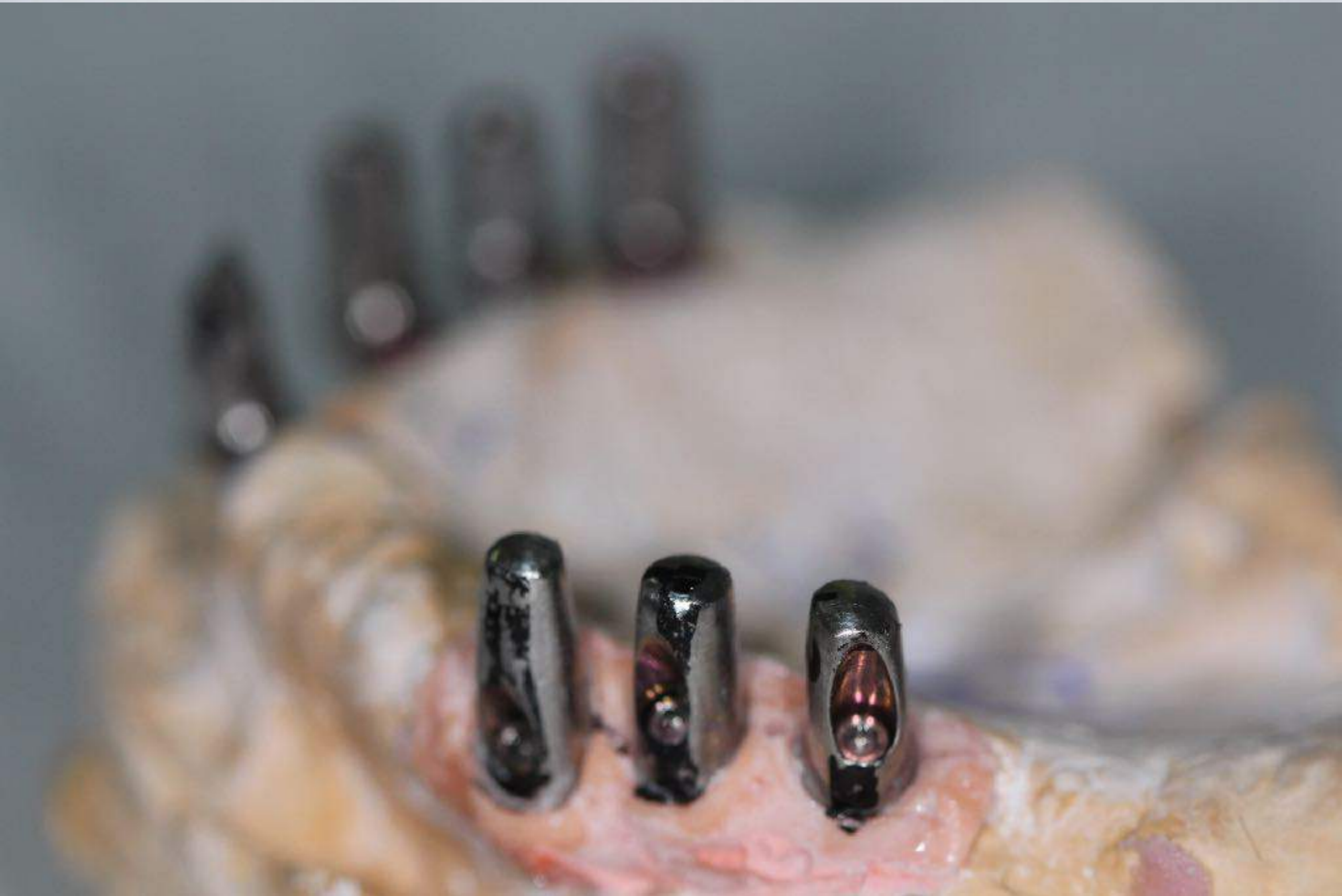
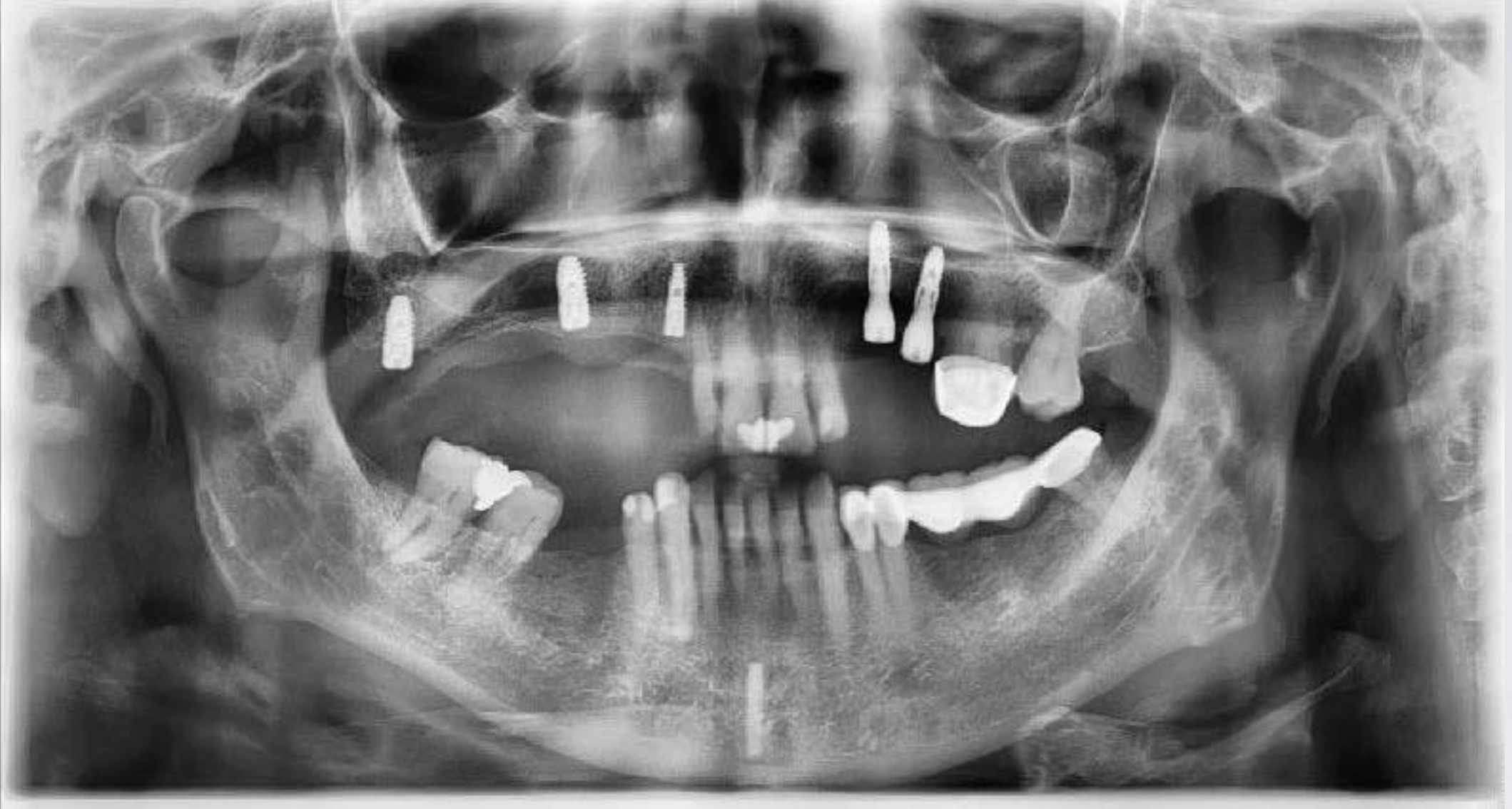


Table 2 Validation of loading protocols for different prosthodontic treatments in the edentulous mandible or maxilla.

	Removable		Fixed	
	Maxilla	Mandible	Maxilla	Mandible
Conventional loading	CWD	SCV	SCV	CWD
Early loading	CD	CWD	CD	CD
Immediate loading	CID	CWD	CWD	CWD
Immediate loading of immediately placed implants	CID	CID	CD	CID

SCV: scientifically and clinically validated – dark green; CWD: clinically well-documented – light green; CD: clinically documented – yellow; CID: clinically insufficiently documented – red



HATAY MUSTAFA KEMAL ÜNİVERSİTESİ, DİŞ HEKİMLİĞİ FAKÜLTESİ

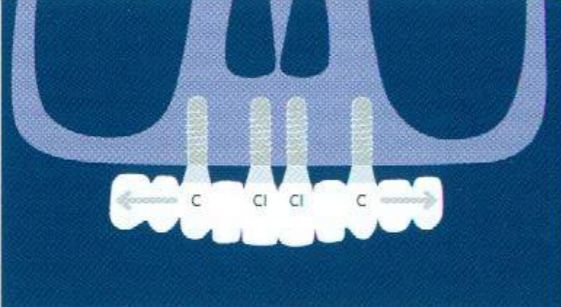
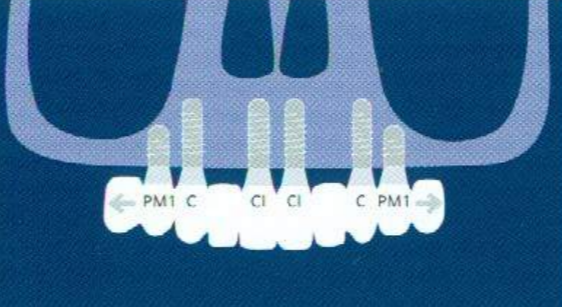
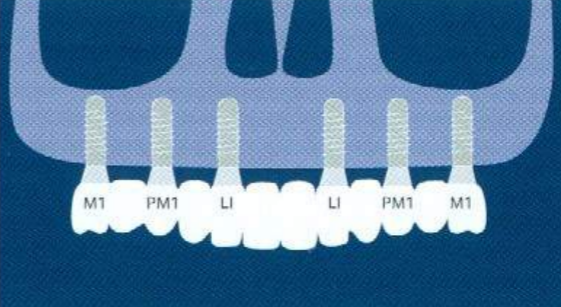
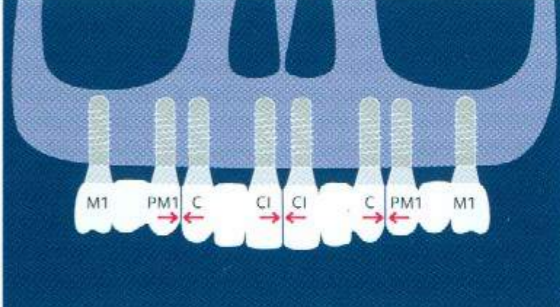
Dr. MUSTAFA ZORTUK

Table 1 Indications for loading protocols with maxillary overdentures.

Implant/prosthetic design				
Conventional loading	CWD	CWD	CD	CD
Early loading	CD	CD	CID	CID
Immediate loading	CID	CID	CID	CID
Retention	Bar design (with or without cantilevers) over four splinted implants	Bar design over six splinted implants	Four free-standing implants with Locator or telescopic crown attachments	Six free-standing implants with Locator or telescopic crown attachments
Prosthesis	Palate-free overdenture	Palateless overdenture	Palateless overdenture	Palateless overdenture
Interarch relation	Adequate interarch space	Adequate interarch space	Reduced interarch space	Reduced interarch space

CWD: clinically well documented – light green  
 CD: clinically documented – yellow  
 CID: clinically insufficiently documented – red  
 M1: first molar, PM2: second premolar, PM1: first premolar, C: canine, LI: lateral incisor  
 →: Optional bar segment as a distal extension

Table 2. Indications for loading protocols with maxillary fixed rehabilitations.

Implant/prosthetic design				
Conventional loading	CD	SCV	SCV	SCV
Early loading	CID	CD	CD	CD
Immediate loading	CID	CWD	CWD	CWD
Implant number and distribution	Four anterior	Six anterior	Six anterior-posterior	Eight anterior-posterior
Prosthesis	Full-arch with distal cantilevers	Full-arch with distal cantilevers	Full-arch	Segmented in four three-unit FPDs*
Clinics	Increased interarch space, adequate bone volume in the anterior maxilla	Increased interarch space, adequate bone volume in the anterior maxilla	Increased interarch space, adequate bone volume in the anterior/posterior maxilla	Increased interarch space, adequate bone volume in the anterior/posterior maxilla

SCV: scientifically and clinically validated – dark green

CWD: clinically well documented – light green

CD: clinically documented – yellow

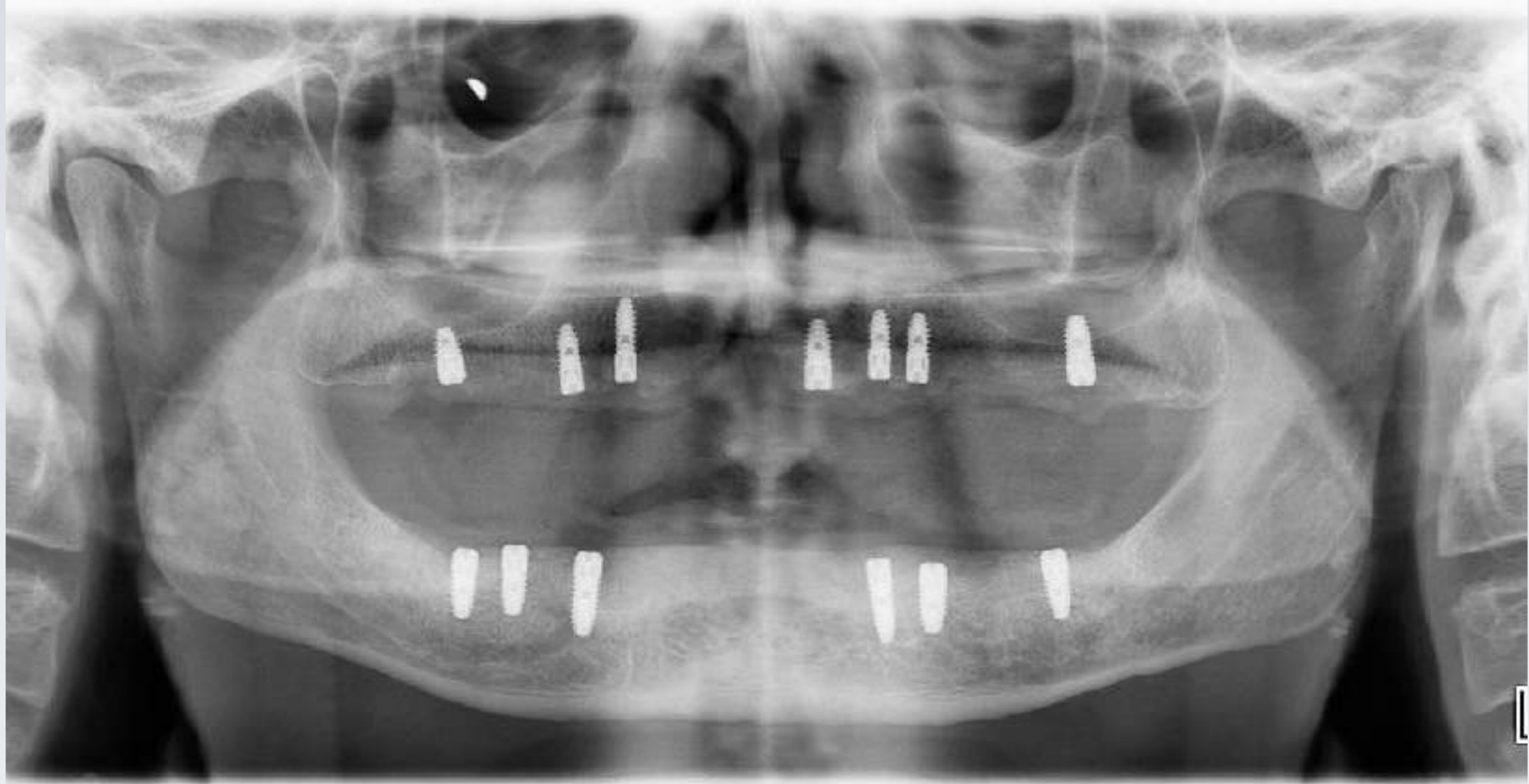
CID: clinically insufficiently documented – red

M1: first molar, PM2: second premolar, PM1: first premolar, C: canine, CI: central incisor, LI: lateral incisor

\*The segmentation design represents the final prosthesis. For fixed transitional prosthesis a full-arch one-piece is indicated.

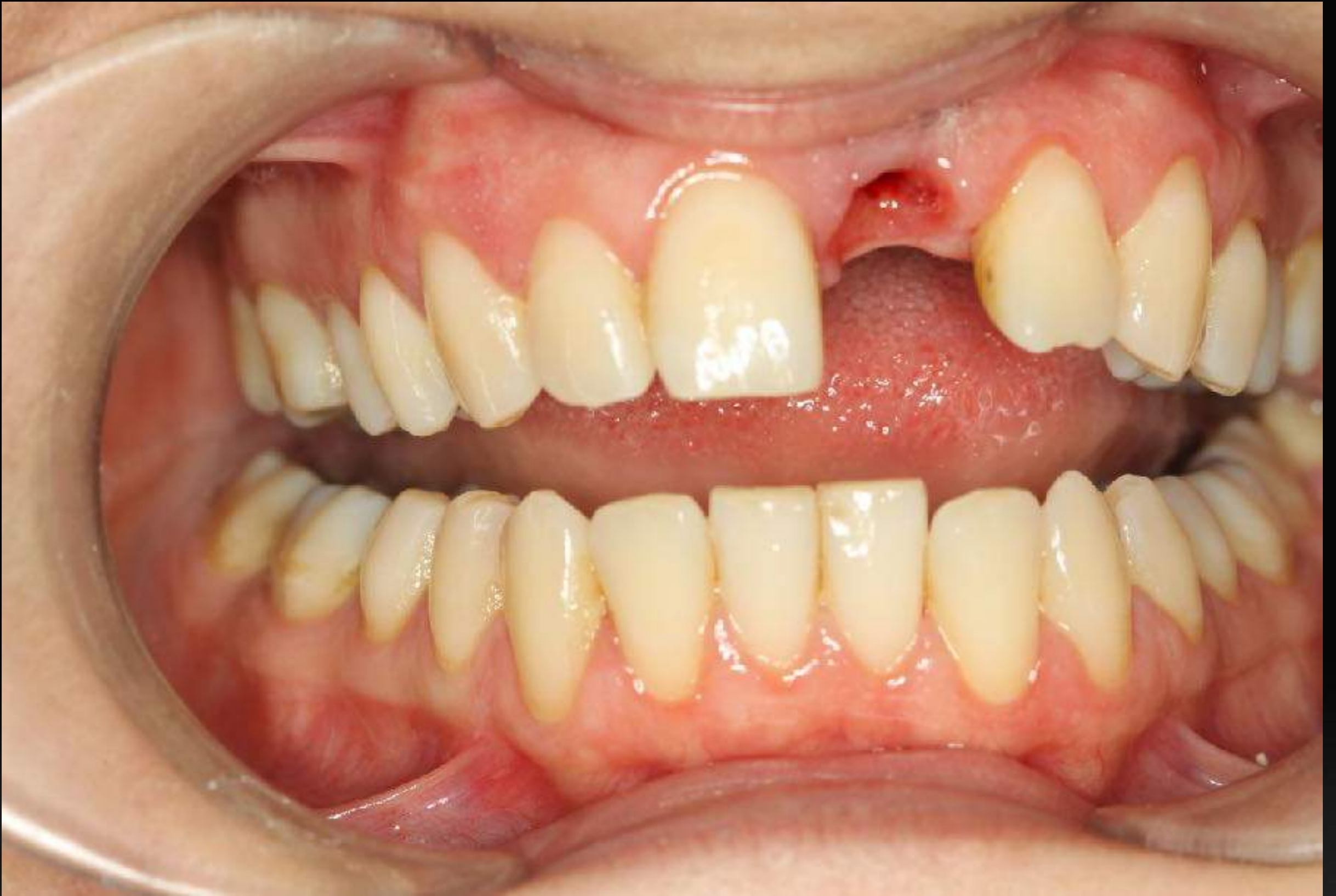→: Cantilever

↔: Segmentation area



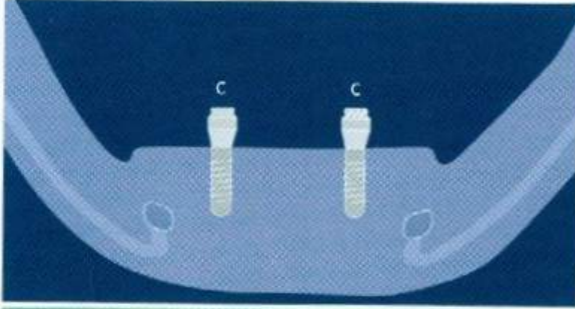
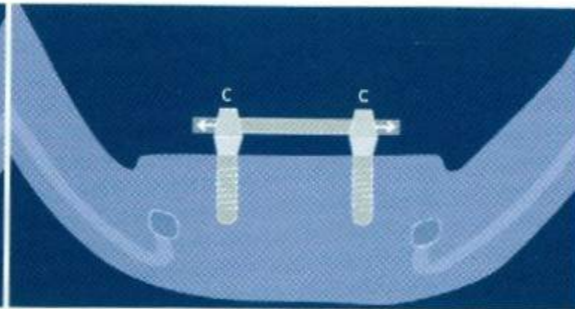
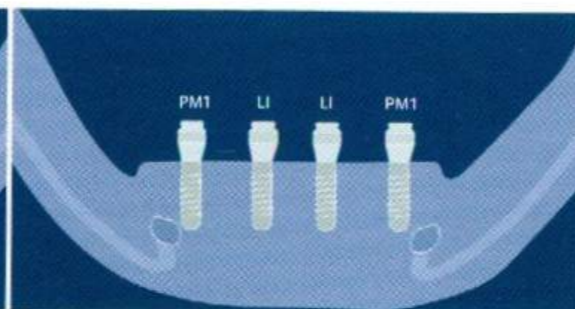
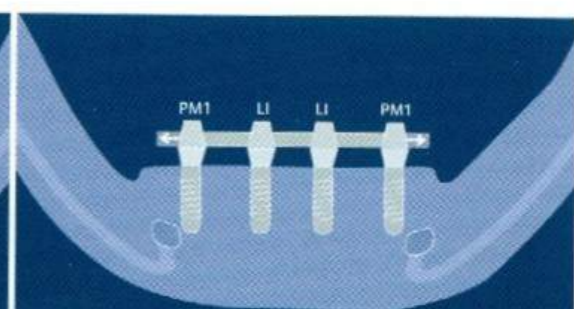
HATAY MUSTAFA KEMAL ÜNİVERSİTESİ, DİŞ HEKİMLİĞİ FAKÜLTESİ

Dr. MUSTAFA ZORTUK



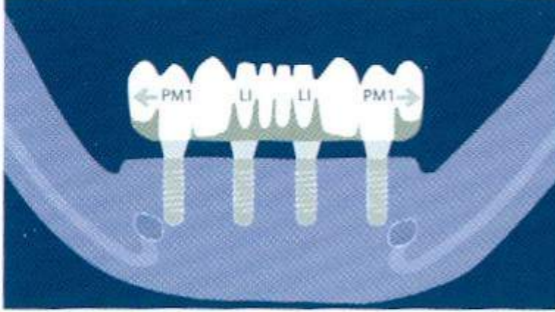
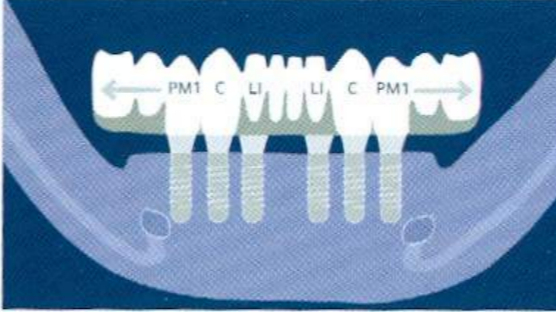
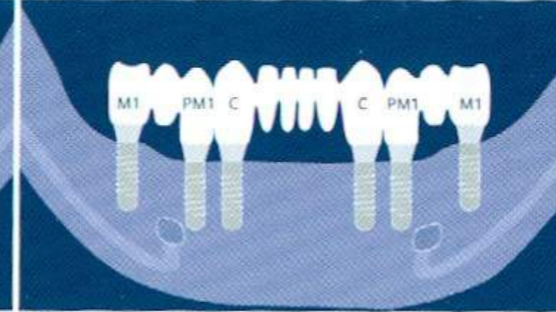
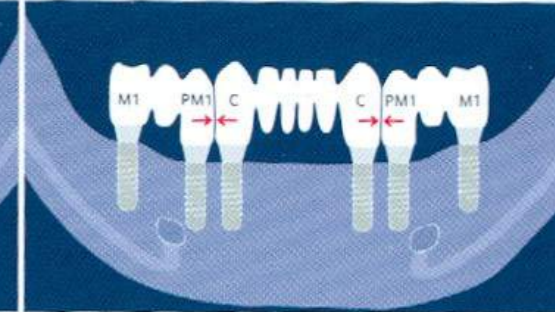
Anterior Bölgede, Geç yükleme

Table 3 Indications for loading protocols with mandibular overdentures.

<b>Implant/prosthetic design</b>				
<b>Conventional loading</b>	SCV	SCV	SCV	SCV
<b>Early loading</b>	CWD	CWD	CWD	CWD
<b>Immediate loading</b>	CID	CD	CD	CWD
<b>Retention</b>	Two free-standing implants with ball or Locator attachments	Bar design over two splinted implants	Four free-standing implants with Locator or telescopic crown attachments	Bar design over four splinted implants
<b>Prosthesis</b>	Mandibular overdenture	Mandibular overdenture	Mandibular overdenture	Mandibular overdenture
<b>Clinics</b>	Adequate/reduced interarch space	Adequate interarch space	Adequate/reduced interarch space	Reduced interarch space

SCV: scientifically and clinically validated – dark green  
 CWD: clinically well documented – light green  
 CD: clinically documented – yellow  
 M1: first molar, PM2: second premolar, PM1: first premolar, C: canine, LI: lateral incisor  
 →: Optional bar segment as a distal extension

Table 4 Indications for loading protocols with mandibular fixed rehabilitations.

Implant/prosthetic design				
Conventional loading	CWD	SCV	SCV	SCV
Early loading	CD	CD	CD	CD
Immediate loading	CD	CWD	CWD	CWD
Implant number and distribution	Four anterior	Six anterior	Six anterior-posterior	Six anterior-posterior
Prosthesis	Full-arch with one-unit bilateral distal cantilevers	Full-arch with two-unit bilateral distal cantilevers	Full-arch in one piece	Segmented into three FPDs*
Clinics	Increased interarch space, adequate bone volume in the anterior mandible	Increased interarch space, adequate bone volume in the anterior mandible	Increased interarch space, adequate bone volume in the anterior/posterior mandible	Increased interarch space, adequate bone volume in the anterior/posterior mandible

SCV: scientifically and clinically validated – dark green

CWD: clinically well documented – light green

CD: clinically documented – yellow

M1: first molar, PM1: first premolar, C: canine, LI: lateral incisor

→←: Segmentation area

\*The segmentation design represents the final prosthesis. For fixed transitional prosthesis, a full-arch one-piece prosthesis is indicated.



Table 5 SAC classification for loading protocols and prosthodontic difficulty level in edentulous patients.

2

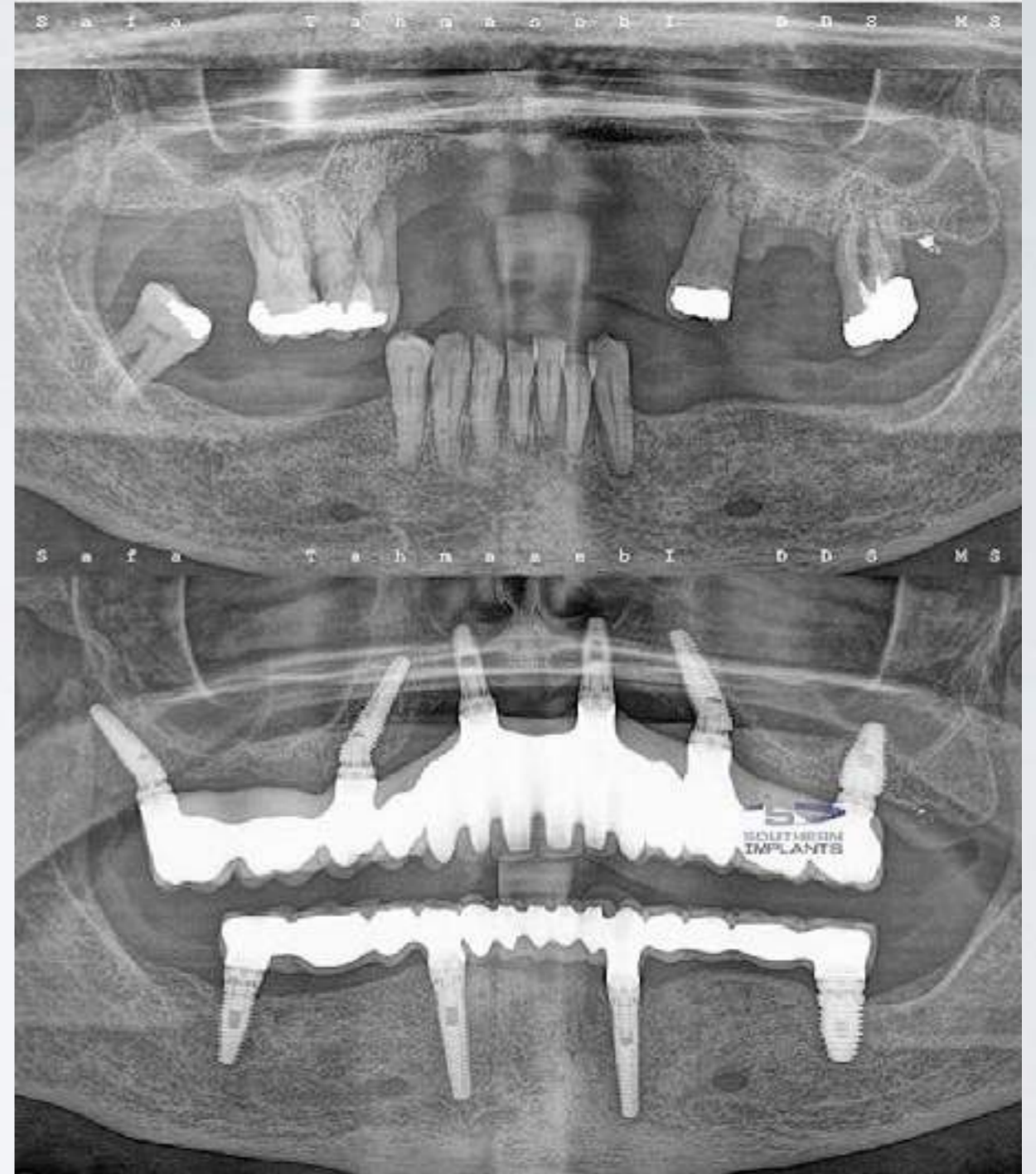
	Removable				Fixed			
	Maxilla		Mandible		Maxilla		Mandible	
	4 implants	≥6 implants	2 implants	≥4 implants	<6 implants	≥6 implants	<6 implants	≥6 implants
<b>Conventional loading</b>	Advanced	Advanced	Straight-forward	Advanced	Advanced	Complex	Advanced	Advanced
<b>Early loading</b>	Complex	Complex	Straight-forward	Advanced	Advanced	Complex	Advanced	Complex
<b>Immediate loading</b>	Not recommended		Advanced	Complex	Complex	Complex	Complex	Complex

☑ İmmediat yükleme için, mandibulada en az 5, maksillada ise 8 implant en iyi şekilde dağıtılıp çift taraflı splintleme etkisi yaratacak şekilde planlanmalıdır.

☑ İmmediat yüklenecek implantların uzunluğu en az 10 mm olmalıdır.

☑ Yerleştirme torku 40 N/cm' den fazla ve primer stabilitesi yüksek olan implantlar yüklenmelidir.

☑ Uzunluğu ve yerleştirme torku istenen değerleri vermeyen implantlar yüklenmemelidir.



- Vida tutuculu, rijit metal dökümlü pasif geçici protezler daha başarılı olacaktır.
- Geçici protezlerde kanat uzantılarından kaçınılmalıdır.
- Geçici protezler iyileşme döneminde çıkarılmamalıdır (Horiuchi ve ark., 2000).
- Osstell cihazı ile yapılan RFA ölçümünde 54 ve üzeri ISQ değeri veren implantlar immediat olarak yüklenebilir.